Histologie 3D de l’œil humain

Michel Paques



Marie Darche

Anna Verschueren

Ysé Borella

Introduction

- Histologie: étude des tissus et de leur structure
- Anatomopathologie (analyse diagnostique) ≠ Histologie en recherche
- Tissus post-chirurgie ou post-mortem

Introduction

Immunohistochimie

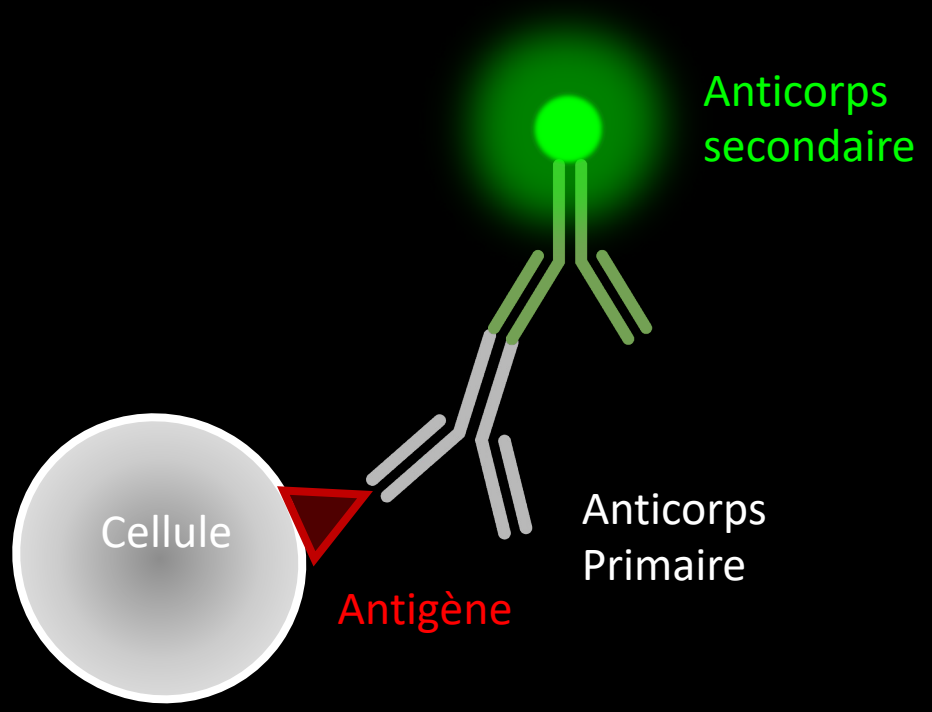

Coupe

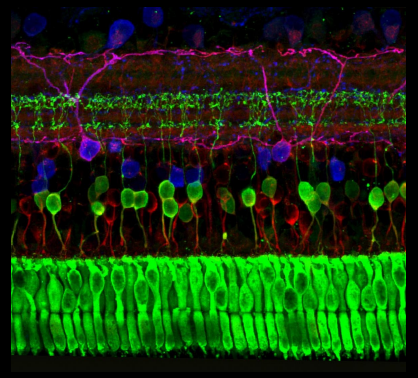

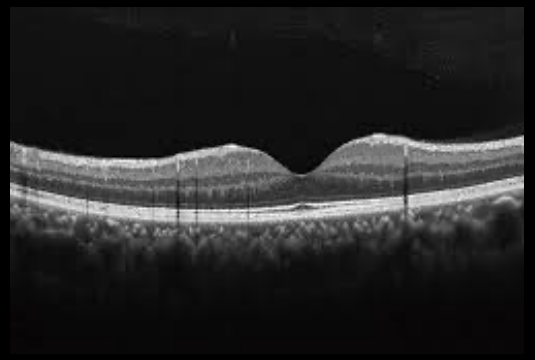

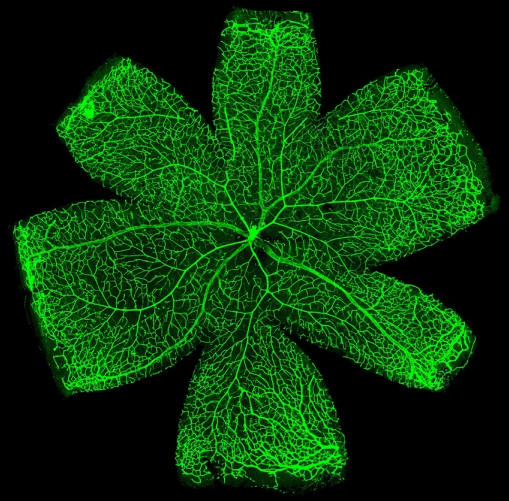

© Graeme Birdsey

Rétine à plat

Exemple d’un cas d’étude:

Femme de 91 ans ; BRVO avec œdème maculaire

Anna Verschueren

Daniela Castro Farias

Ysé Borella

Michel Paques

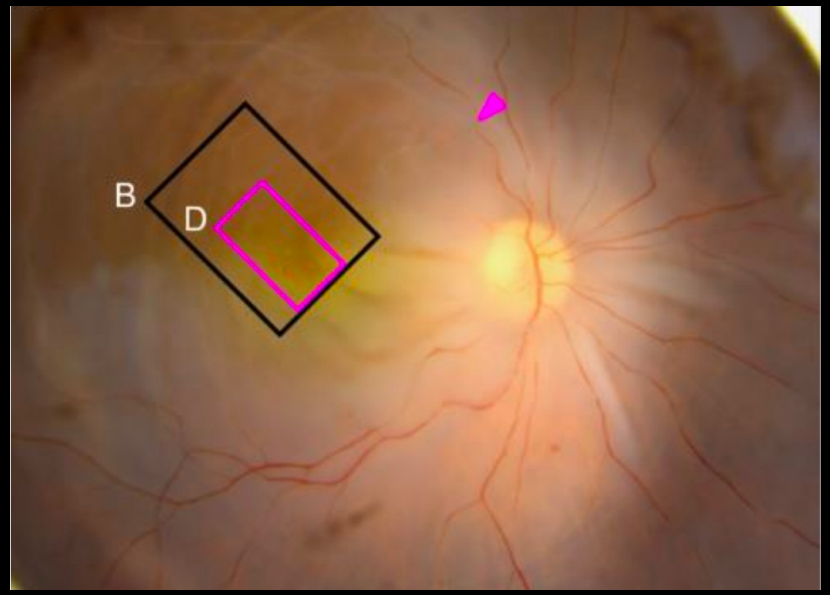

Fond d’oeil post mortem

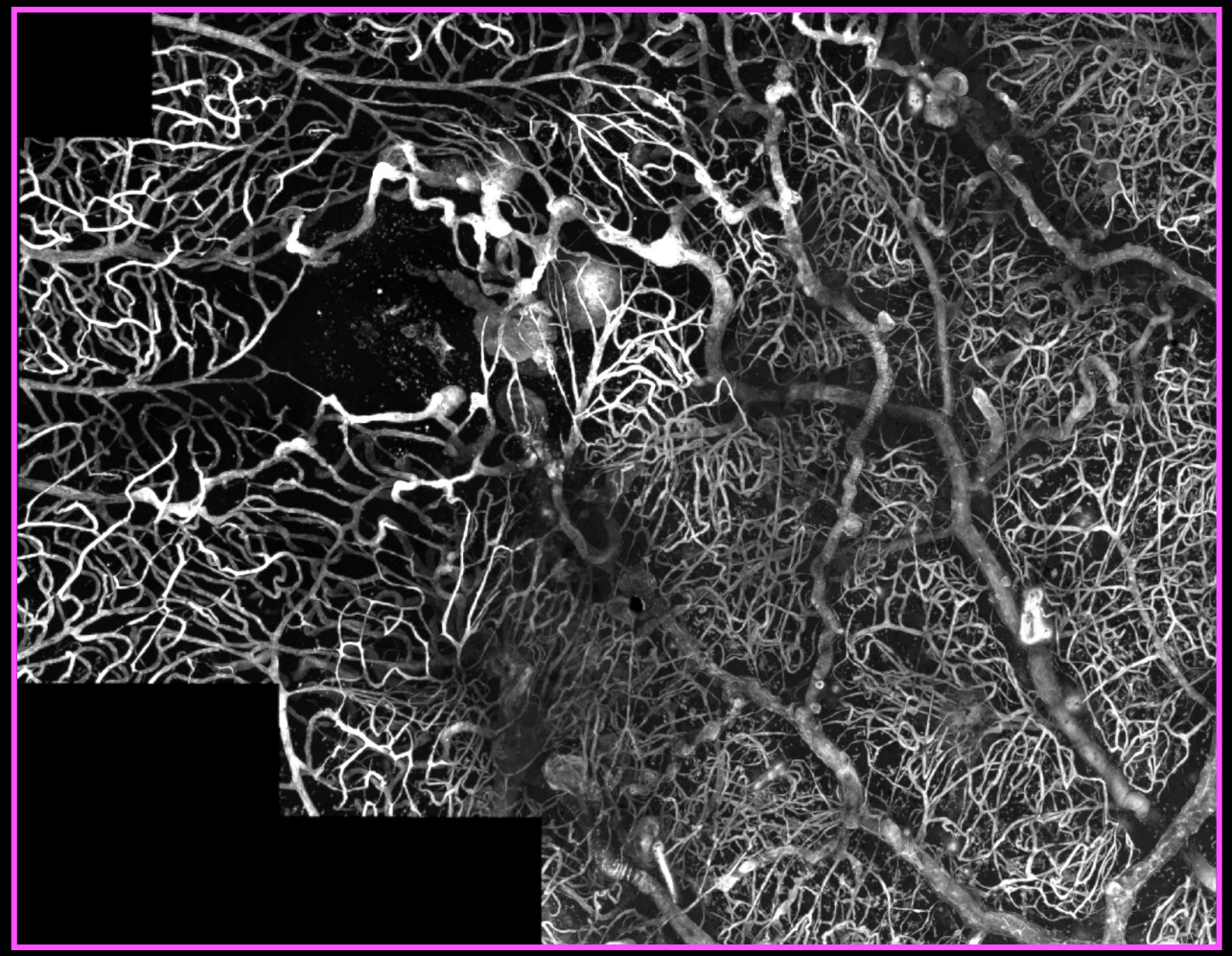

Col IV

Imagerie confocal: Fovéa autour de la ZAC

Anomalies vasculaires

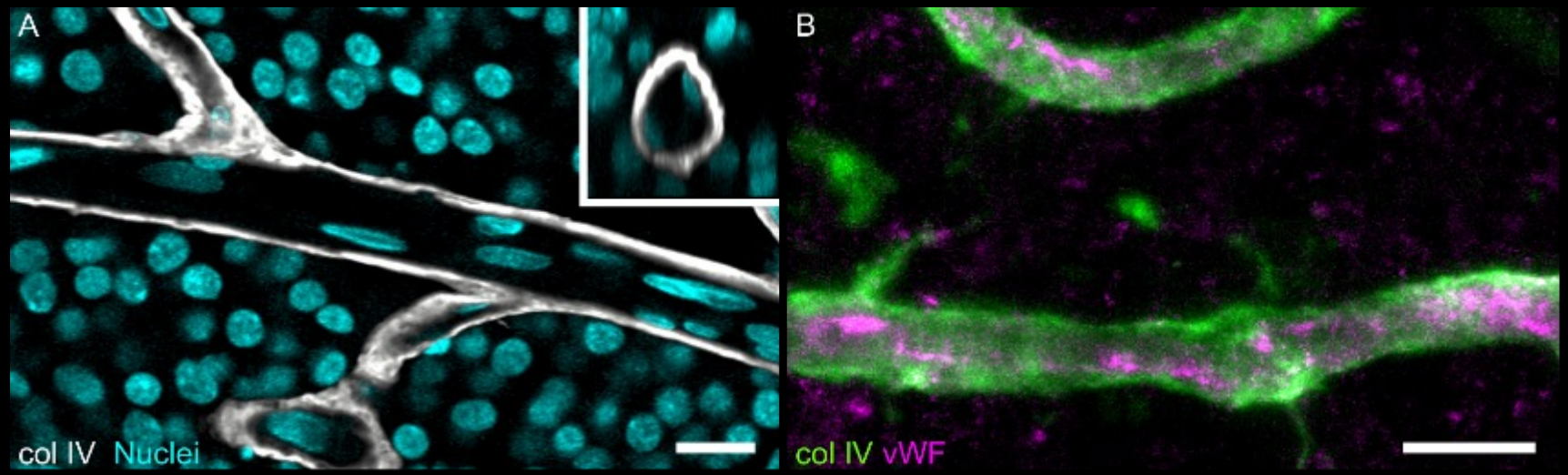

Anomalies vasculaires

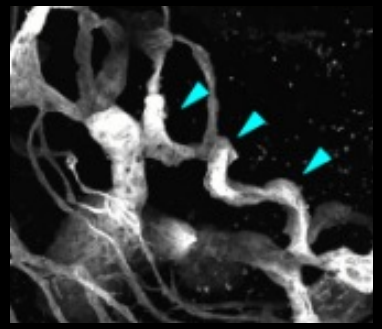

Veine collatérale dans la ZAC

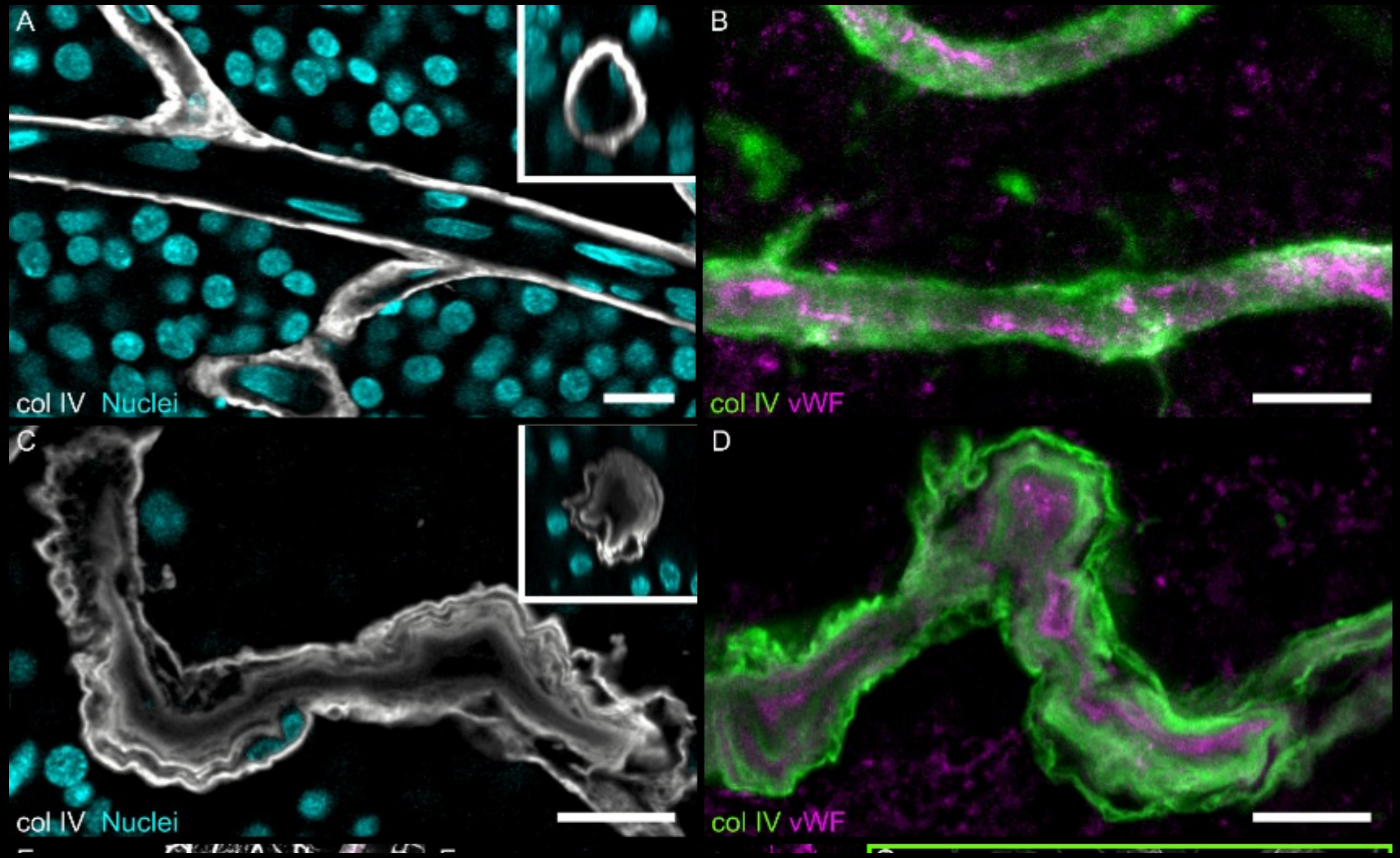

Artères anormales: Double lumen

Col IV

αSMA

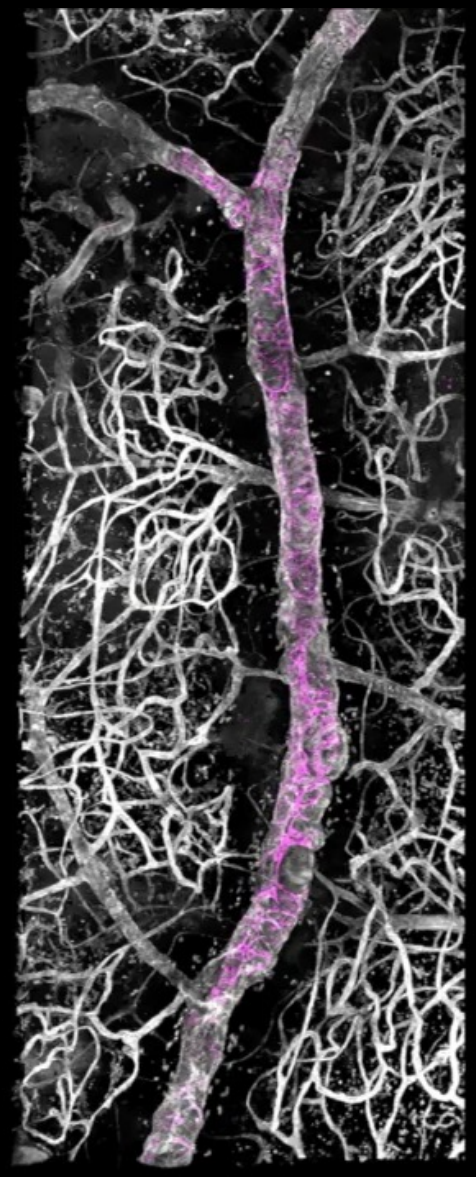

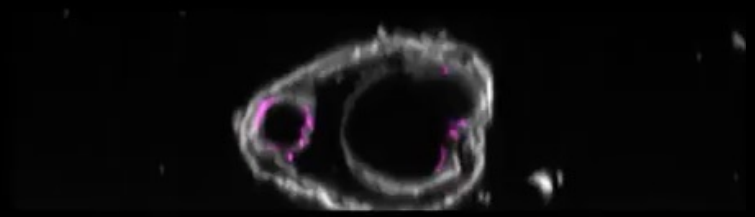

Diversité des dilatations capillaires (anévrismes)

Size

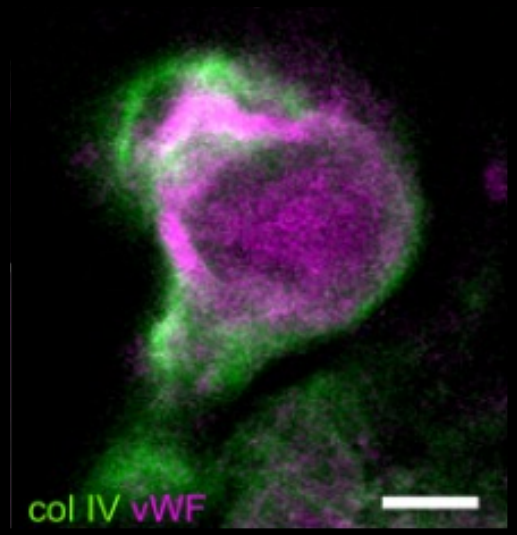

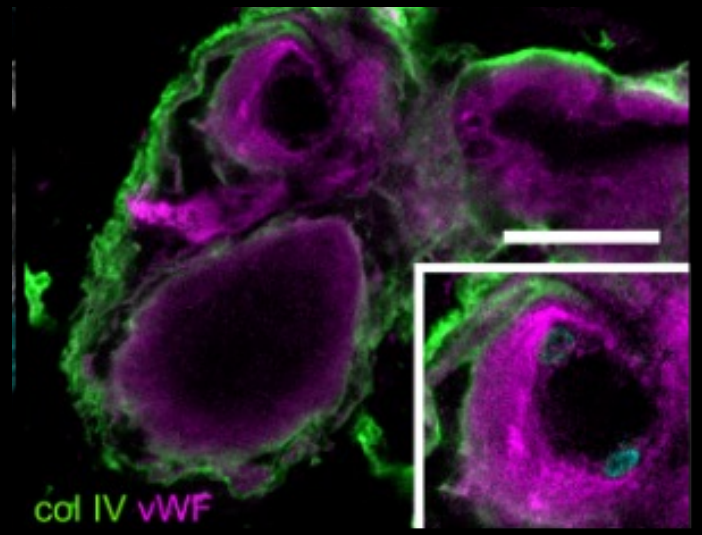

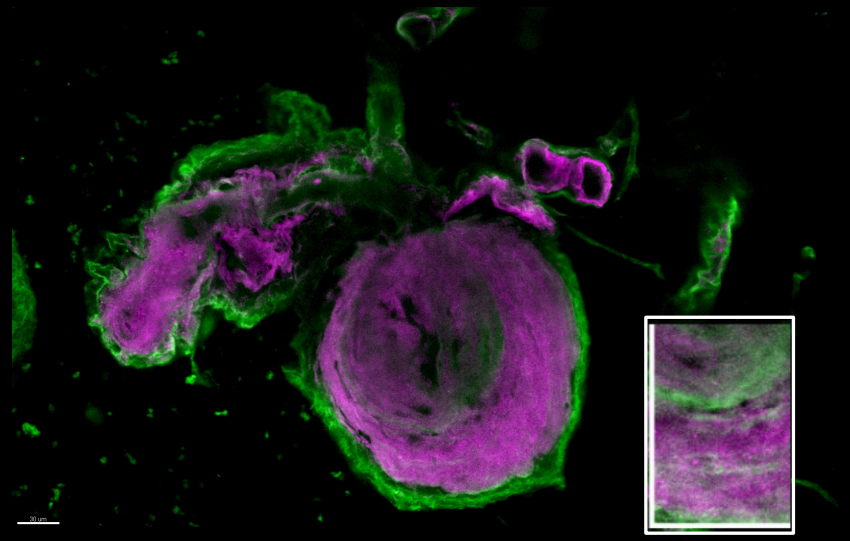

- Petites protuberances
- Pas de lumen
- Fins murs de collagène
- Remplis de vWF

- Larges dilatations vasculaires
- Lumens partiels
- Mur en collagène épaissis
- Couches de vWF

- Enorme (300um)
- Pas de lumen
- Murs de collagen épais
- Rempli de vWF (vWF et collagène en couches)

Carte des anomalies vasculaires dans la Fovea

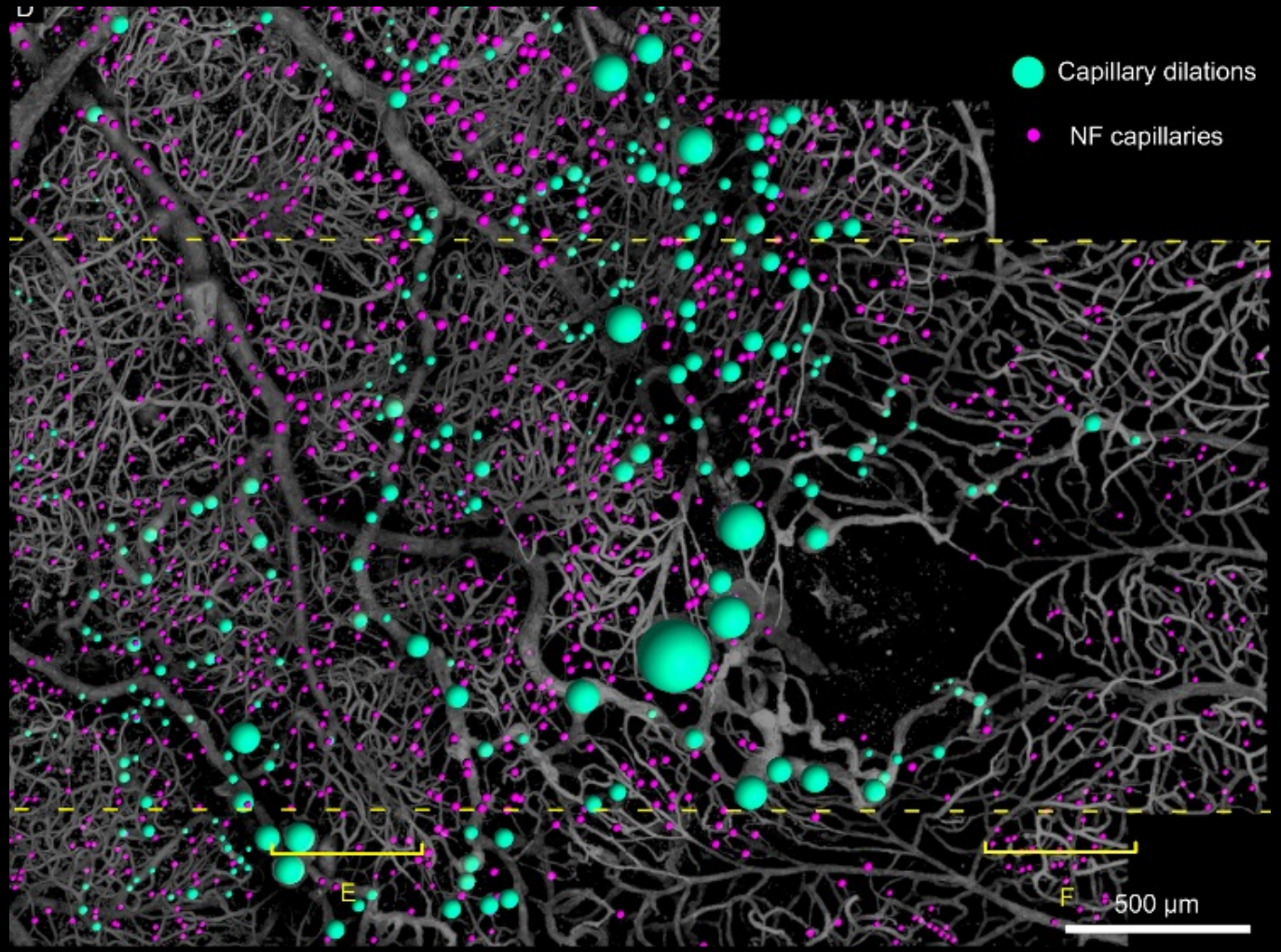

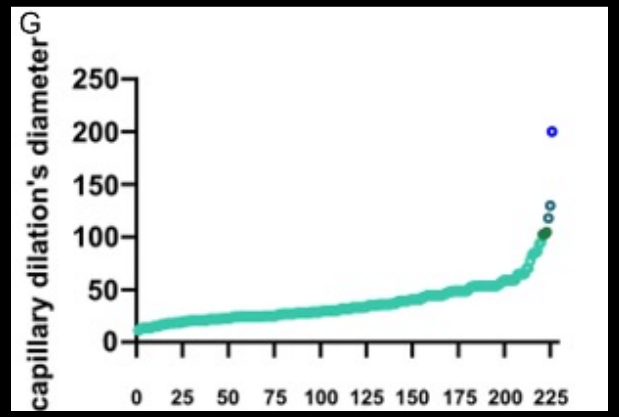

Taille des dilatations capillaires. Rares (anneaux bleux) sont les anomalies de plus de 100µm

Telangiectatic capillary (TelCap)

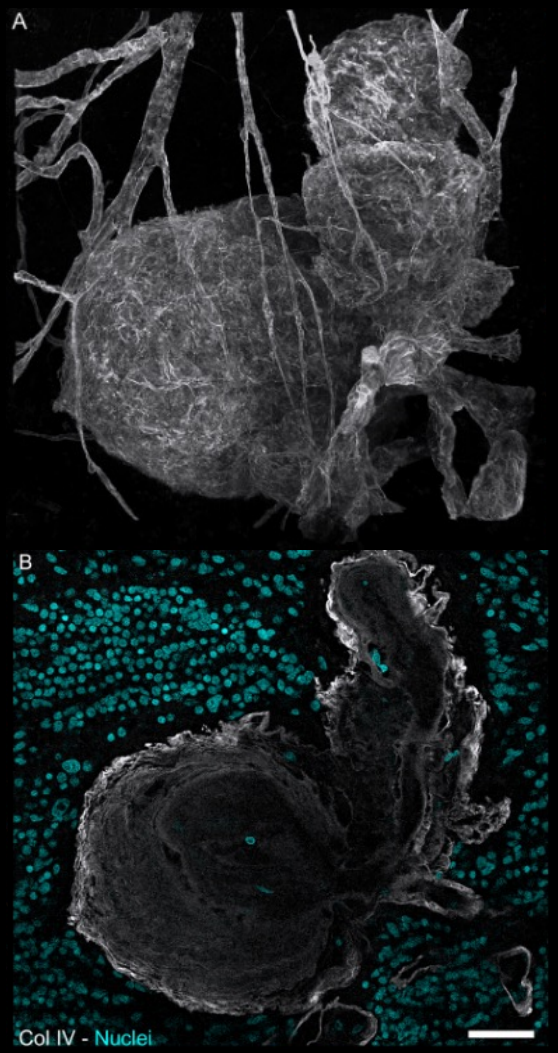

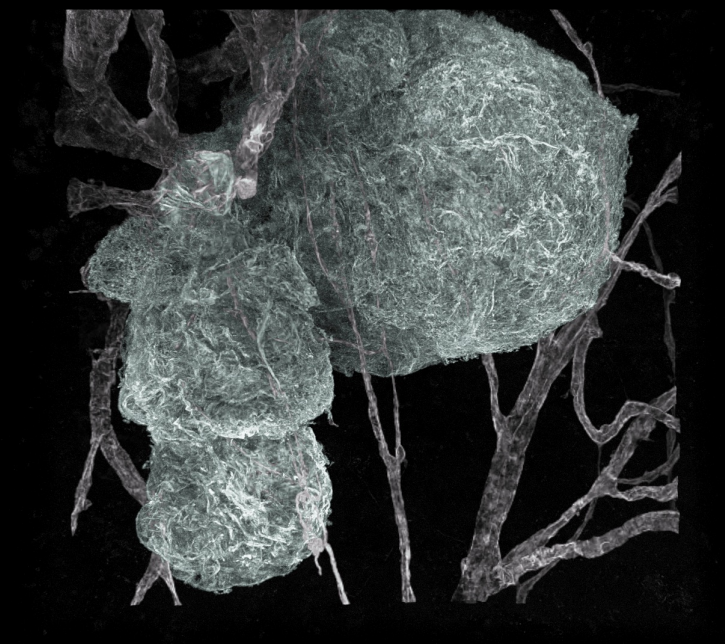

3D view

Coupes

→ Un lien entre structure et observations cliniques ?

Journal of Anatomy

ORIGINAL ARTICLE | Full Access

Confocal microscopy of telangiectatic capillaries (TelCaps) and other features of microvascular remodeling following branch retinal vein occlusion

Marie Darche, Anna Verschueren, Daniela Castro Farias, Ysé Borella, Michel Paques

First published: 24 August 2022 | https://doi.org/10.1111/joa.13743 | Citations: 1

Sorbonne Université

SECTIONS PDF TOOLS SHARE

Abstract

Branch retinal vein occlusion (BRVO) is a frequent retinal vascular disease that may cause extensive microvascular remodeling leading to severe visual impairment. Little is known regarding the histology of non-neovascular microvascular remodeling. Here, we examined by confocal microscopy the structure of retinal microvessels of a donor eye with longstanding BRVO. The post-mortem retina of a 91-year-old woman that had superotemporal BRVO for 2 years was examined by confocal microscopy after anti-collagen IV (collIV), alpha-smooth muscle cell (αSMA), and anti-von Willebrand factor (vWf) immunolabeling. In the retinal quadrant affected by BRVO, extensive vascular remodeling affected all vessels, from arterioles to venules, including the foveal avascular zone. Most affected vessels were either irregularly dilated or, on the opposite, reduced to micrometric-size CollIV positive, vWf negative, nuclear-staining negative strings. Telangiectatic capillaries of various sizes and shapes were seen, the largest one (233 µm) being located in the parafoveal area. Some telangiectatic capillaries had a thick,

Article publié dans le journal of Anatomy en 2022

Imagerie *in toto* de l'oeil ?

- Histologie Classique limitée
  - Artefacts de dissections
  - Profondeur de champ réduite/tissus isolés
  - Comparaison d'images cliniques/histologiques compliquées

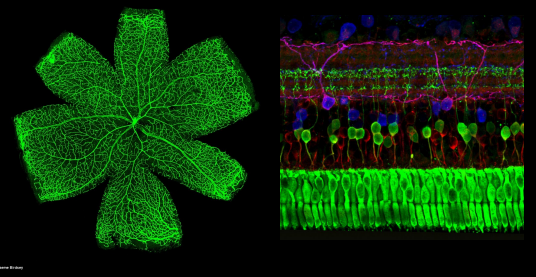

Imagerie *in toto* de l'oeil ?

- Histologie Classique limitée
  - Artefacts de dissections
  - Profondeur de champ réduite/tissus isolés
  - Comparaison d'images cliniques/histologiques compliquées

- *In toto* : Organes entiers ou échantillons centimétriques

Imagerie *in toto* de l'oeil ?

- Histologie Classique limitée
  - Artefacts de dissections
  - Profondeur de champ réduite/tissus isolés
  - Comparaison d'images cliniques/histologiques compliquées

- *In toto* : Organes entiers ou échantillons centimétriques

  → Transparisation (clearing)

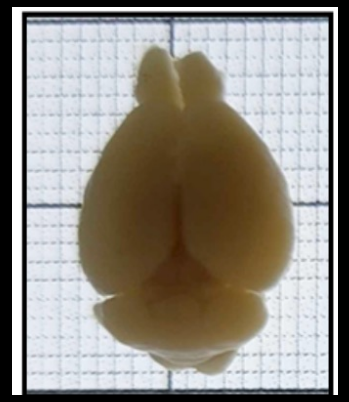

Cerveau de souris
Avant transparisation



Cerveau de souris
Après transparisation

Imagerie *in toto* de l'oeil ?

- Histologie Classique limitée
  - Artefacts de dissections
  - Profondeur de champ réduite/tissus isolés
  - Comparaison d'images cliniques/histologiques compliquées

- *In toto* : Organes entiers ou échantillons centimétriques

  → Transparisation (clearing)

- Imagerie *In toto :*
  - Imager des échantillons intacts (physiopathologie à l'échelle de l'organe)
  - Une imagerie: phénomène isolé à l'organe entier
  - Organisation dans l'espace préservée
  - Comparaison images cliniques/histologiques

Oeil de souris entier

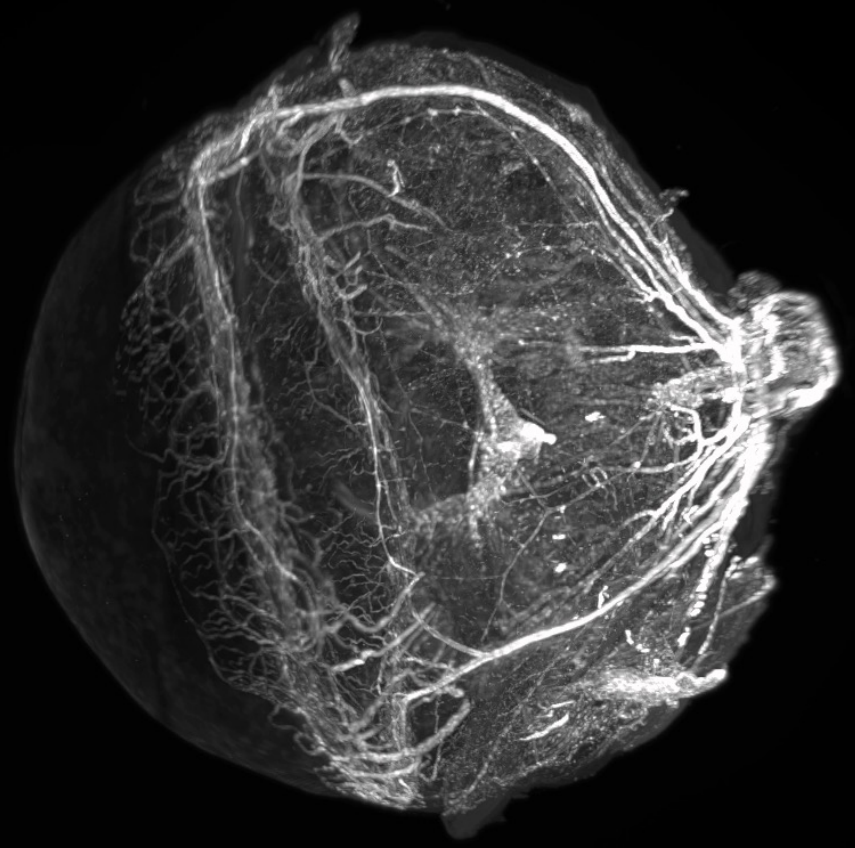

Blanc: CD31 (cellules endothéliales des vaisseaux)

Darche et al, 2022, Communication biology

communications biology

Explore content | About the journal | Publish with us

nature > communications biology > articles > article

Article | Open Access | Published: 27 October 2022

Three-dimensional characterization of developing and adult ocular vasculature in mice using *in toto* clearing

Marie Darche, Anna Verschueren, Morgane Belle, Leyna Boucherit, Stéphane Fouquet, José Alain Sahel, Alain Chédotal, Ilaria Cascone & Michel Paques

Communications Biology **5**, Article number: 1135 (2022) | Cite this article

1993 Accesses | **9** Altmetric | Metrics

Abstract

The ocular vasculature is critically involved in many blinding diseases and is also a popular research model for the exploration of developmental and pathological angiogenesis. The development of ocular vessels is a complex, finely orchestrated sequence of events, involving spatial and temporal coordination of hyaloid, choroidal and retinal networks. Comprehensive studies of the tridimensional dynamics of microvascular remodeling are limited by the fact that preserving the spatial disposition of ocular vascular networks is cumbersome using classical histological procedures. Here, we demonstrate that light-sheet fluorescence microscopy (LFSM) of cleared mouse eyes followed by extensive virtual dissection offers a solution to this problem. To the best of our knowledge, this is the first 3D quantification of the evolution of the hyaloid vasculature and of post-occlusive venous remodeling together with the characterization of spatial distribution of various cell populations in ocular compartments, including the vitreous. These techniques will prove interesting to obtain other insights in scientific questions addressing organ-wide cell interactions.

Introduction

The choroidal, retinal and hyaloid vessels jointly support the development and metabolism of the eye, hence a comprehensive approach of ocular development,

Article sur l'œil entier transparisé de souris publié en 2022.

Le développement d'un protocole adapté à l'œil humain entier est en cours de développement

A ce jour:

- 5 nerfs optiques isolés, 10 segments antérieurs et 12 yeux entiers imagés avec le nouveau protocole ClearEye

- Donneurs : 16 à 94 ans sains, en provenance des Etats unis

Publication d'ici quelques mois puis début de l'imagerie sur des échantillons pathologiques (en priorité OVR et DMLA)